

# "The Hockey Groin"

## An Effective Treatment for a Groin Pull

Many competitive athletes encounter a "groin pull" in their athletic endeavors. Depending on the severity, a groin pull can range from a slight stretching, to a complete rupture of the muscles that attach the pubic (pelvis) bone to the thigh (femur) bone.

A groin pull or strain specifically affects the "Adductor" muscles. (Adductor; meaning, moves part closer to the midline of the body) These muscles are located on the inside of the thigh, and help to bring the legs together.

The adductor muscles consist of Adductor Brevis, Adductor Magnus, Adductor Longus, Iliopsoas, Pectineus and Gracilis. Adductor Longus, Iliopsoas / Psoas and Pectineus are statistically most susceptible to injury.

### What Causes a Groin Pull?

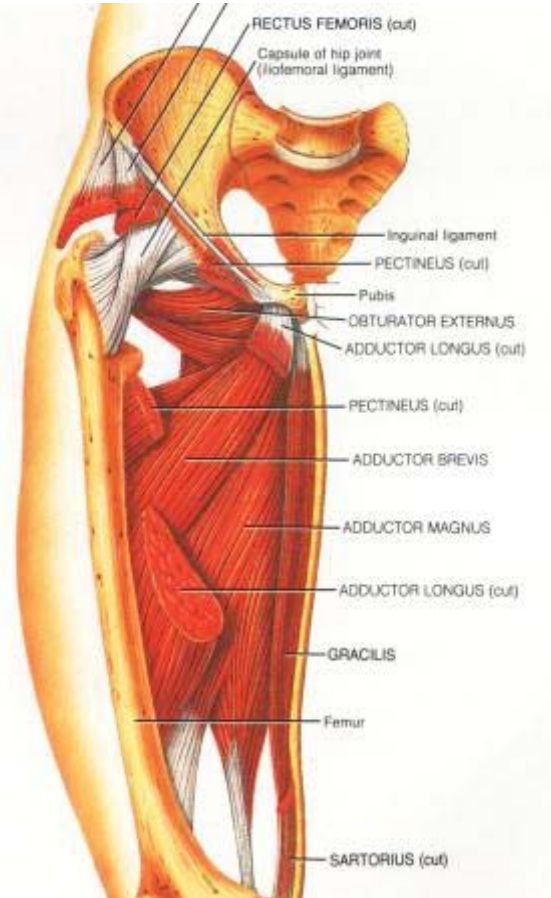
Sports that require a lot of rapid direction change are most susceptible to groin injuries. Other activities like kicking, jumping and rapid acceleration / deceleration place increased strain on the groin muscles. Any activity that creates sudden loaded abduction or adduction of the groin muscles can trigger a "pulled groin". Hip misalignment also can manifest asymmetric *hyper-recruitment* of a muscle group. Conversely, a groin pull can also create asymmetry in hip alignment.

### How to Prevent a Groin Pull?

Prevention comes down to several factors. A thorough warm-up, physical conditioning and alignment of the muscular attachment points (Pelvis/Sacrum/Ileum/Lumbar Spine) ie: flexibility, range of motion & strength.

**First**, it is important to encourage capillary filling in the muscle belly by warming the muscle groups up slightly before stretching. This causes tendons, which attach muscle to bone, to receive a more efficient stretch.

**Second**, flexible muscles and tendons are extremely important in the prevention of most strain or sprain injuries. When muscles and tendons are tight and stiff, it is easy for them to be pushed beyond their natural range of movement, which can cause strains, sprains, and "pulls". It is also very important to stretch properly. I frequently witness seasoned hockey players at every level improperly stretching their adductor muscles. Please ask for a demonstration of how to isolate the psoas and pectineus musculature when stretching.



## What is the treatment for groin pulls and how long does it take to recover?

For all the similarities, every groin pull is as different, as are the athletes that have them. The recovery depends on a lot of factors. Age, level of fitness, severity of the injury and diligence with respect to rehabilitation all contribute to recovery times.

Conservative treatment is recommended for non-avulsed or “full thickness” torn muscles. Most of us are familiar with R.I.C.E. (Rest, Ice, Compression and Elevation) and P.I.E.R. (Pressure, Ice, Elevation and Rest) principles for immediate treatment, but after this, many patients and physicians are stuck. I have found that a combination of “RICE”, Ultra-sound Phonophoresis, Travell & Simmons myo-fascial technique, Active Release Technique, Spray & Stretch technique with muscle specific isolated stretching, and even Cold Laser Therapy (CLT) is highly effective in promoting a faster return to athletics, occasionally accompanied by the use of compression shorts. Anecdotal evidence suggests these modalities can expedite the return to full groin health by as much as 65%.

Many physicians advocate the use of Corticosteroids for the treatment of groin pulls due to the inflammatory nature of the injury. The use of corticoid steroids with an acute groin pull is controversial. Corticosteroids are catabolic and many believe that their use may loosen the symphysis and result in a lack of integrity of the structure at the tendinous origin/insertion (*Fricker, 1997*).

Scar tissue is an inevitable sequelae of a groin pull if not properly treated. Unfortunately scar tissue is often the cause of repeat offender groin pulls. When muscle fibers elongate past their normal range of eccentric/concentric motion they create micro (or sometimes macro) tears. Fibroblastic responses create a matrix of scar tissue to fill in the breached muscle fibers. Unfortunately this scar tissue does not have the same degree of flexibility, as healthy muscle tissue and consequently, it will encourage future groin pulls and elongation of the scar tissue.

**Ultrasound phonophoresis** (*phonophoresis is the process of injecting an element into the body by mixing it with ultra-sound gel*) followed by **Active Release Technique** [ART] has been proven to be highly efficacious in reducing scar tissue while encouraging faster soft tissue healing. For the adductor group, I use the ultrasound to inject water-soluble Vitamin E as it has also been proven to be successful in reducing scar tissue. Using ultrasound and water-soluble Vitamin E in concert with **ART** enhances two proven methods of scar tissue reduction and facilitates faster healing of the adductor group.

Often when the groin pulls the pelvis becomes misaligned. Therefore, it is also important to assess proper alignment of the pelvis in the correction process as misalignment can cause the stride to shorten and improper recruitment of muscle fibers leading to future groin pulls. The anterior 1/3 of the psoas fibers attach to the diaphragm and consequently, conditions involving severe psoas restriction has even been known to cause restricted breathing. Due to the nature of the attachment point of the psoas it can also create an axial load on the spine and discs when traumatized. Therefore, in addition to the aforementioned modalities Manipulation and Decompression Technique are strongly recommended to balance out the hips and spine. Logically it seems that the hips were either; unbalanced in the first place, contributed to the cause of the groin pull ---or--- they will certainly become unbalanced as a result of the groin pull.

The injury usually is focused at the musculotendinous junction and involves disruption of the fibers to various degrees and occasionally, hematoma formation, which may delay healing. These weakened areas are repaired by fibroblasts, but they remain susceptible to repeat injury for a long time (*Lynch, 1999*). In fact, in a review of 1292 professional Hockey players, those with a previous groin injury had more than double the risk of repeat injury than an athlete without previous groin insult. Furthermore, in a study of groin injuries, veteran hockey players had an injury rate 5 times greater than that of rookie players (*Emery, 2001*). Approximately, 26% of all N.H.L. injuries in 1997-98 were associated with the groin musculature.

It is important to rule out Athletic Pubalgia, Apophysitis, Osteitis Pubis, Avulsion Fracture or Slipped Capital Femoral Epiphysis.

The groin may also be injured from a sudden violent force (i.e. when a skate is taken out from underneath player i.e.: “slue-foot”). When a groin injury occurs, the first and foremost thing to do is reduce the swelling and inflammation right away. The aforementioned modalities are effective in this regard. Rest is also an extremely

important factor, and skating should not be attempted again until full strength & range of motion in that groin is regained. Unfortunately, the hockey player is not always the best judge of when to return. They will often put the team ahead of their own well-being. Too many hockey players return too soon following a groin injury or fail to get the correct treatment and aggravate it further, thereby increasing their total time away from the rink. An injured player should not return until a sports physician decides that the condition is adequately healed.

#### Signs and Symptoms of "The Hockey Groin":

1. Pain with motion or stretching of the hip joint. Usually located on the inside, and can sometimes be very close to the pubic bone.
2. Muscle spasm or weakness in the abdomen or thigh. (If the pain is more associated in the abdomen region, get it assessed immediately. This may be something other than "The Hockey Groin", such as a hernia).
3. Swelling or sub-dermal mass around the groin.
4. Variable loss of strength depending upon the severity of the injury.
5. Tenderness to the touch.

Prevention stretches / on ice exercises:

**AAPN stretch-Abducted Anterior Pelvic Nutation stretch:** Kneeling with shin pads on the ice, allow the knees to slowly separate. The trunk will flex and the butt will approximate the heels of your skates. When you have obtained a minimal stretch gradually push the pelvis forward and straighten the back to an upright position while stabilizing the upper body against either an upright stick or against the boards. Then extend one leg and place the inside of one skate against the dasher board and gradually push into the boards with the pelvis and the inside of the skate while keeping the back vertical and straight.

**Stick stretch** - Sit with your feet pulled apart with the stick. Push the feet to the side, bend forward from the hips and feel a stretch on the inside of the thigh. (Hold 30 seconds, 2 times). Keep your back straight.

**Lunge stretch** – Kneeling on the injured side knee with the opposite foot in front. Lean forward until a stretch is felt in the front groin area (Hold 30 seconds, 2 times). Keep your back straight.

#### **Diagnostic Evaluation for Athletic Return:**

You should be able to do 10-yard dry-land figure-eight runs, first at half speed, then at full speed, - You should be able to jump on both legs without pain, and jump on the injured leg without pain. A thorough evaluation from a Health Care Professional with advanced training in Sports Injury is recommended before returning to athletics.

Written for hockey players by hockey players.

**Dr. Alden Clendenin DC, CCSP**  
Chicago Chiropractic & Sports Injury Center  
2654 N. Lincoln Ave.  
773-529-5670

**Dr. Chris Bocci DC, CCSP**  
Loop Chiropractic & Sports Injury Center  
29 S. LaSalle, Suite 1200  
312-236-9355



Illustration 1: Mary Albury-Noyes

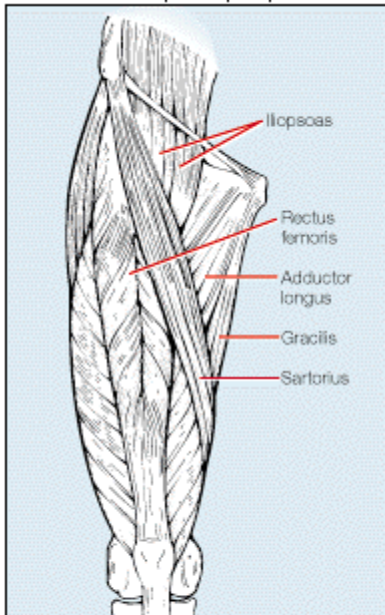


Figure 1. Anterior view of muscles that, when injured, can produce groin pain. Musculo-tendinous injuries in this region most often involve the adductor longus muscle but can also include the iliopsoas, rectus femoris, sartorius, or gracilis muscles.



Illustration 2: Mary Albury-Noyes

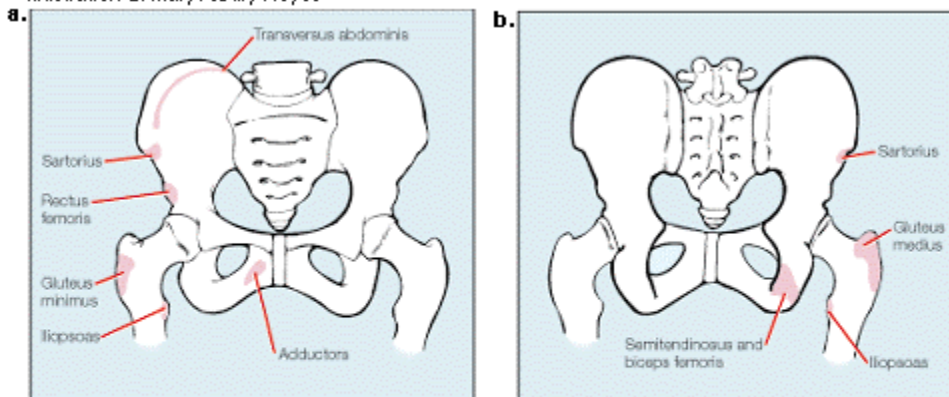


Figure 2. Anterior (a) and posterior (b) views of hip and pelvis muscle attachments where avulsion fractures can occur. With an avulsion fracture of the sartorius, pain will occur at the anterior superior iliac spine. With an avulsion of the rectus femoris, pain will be at the anterior inferior iliac spine. An avulsion of the adductor muscle group will cause tenderness at the pubic symphysis, while the transversus abdominis will be felt at the iliac crest. Semitendinosus and biceps femoris (hamstring) avulsion causes tenderness over the ischial tuberosity. Avulsions involving the gluteus medius and minimus lead to tenderness over the greater trochanter of the femur, while an iliopsoas avulsion causes tenderness over the lesser trochanter.